

Chicken Wing Dissection

How do the muscles, bones, and tendons work together to move a joint of a chicken wing and how do they compare to a human arm?

Although many differences exist between the anatomy of humans and chickens, one structure that shows similarities in muscle pairing and range of motion is a bird's wing. In this activity you will study chicken wing structure and function, which is comparable to that of the human arm.

Bones of the Human Arm

The arm reaches from the shoulder to the wrist. It consists of two basic parts:

- (1) the **upper arm**, which extends between the shoulder and the elbow, and
- (2) the **forearm**, which extends between the elbow and the wrist.

The upper arm is formed by one long bone, the **humerus**. The top end of the humerus is rounded and fits into a cup-shaped depression in the scapula, or shoulder bone, forming a ball-and-socket joint. Ball-and-socket joints allow for circular movement.

The two bones of the forearm are the **radius** and the **ulna**. The ulna is fixed in position, but the radius can rotate over the ulna. This makes rotation of the forearm possible in motions such as twisting a screwdriver.

Skeletal Muscles of the Human Arm

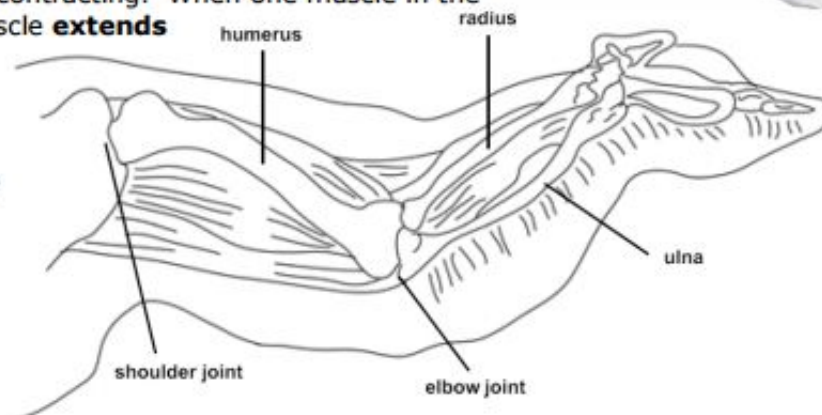
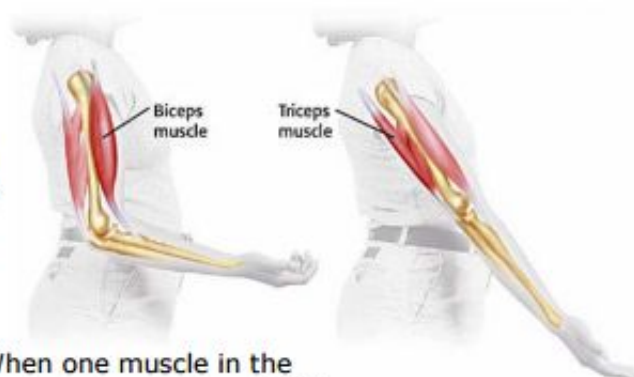
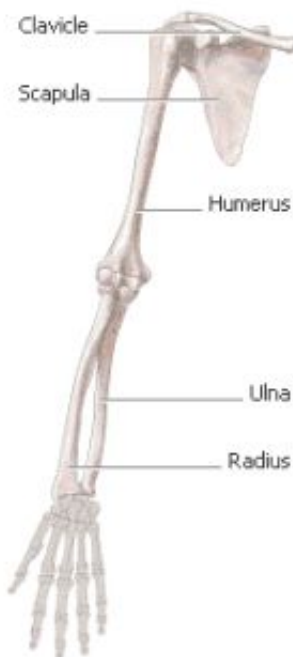Skeletal muscles are responsible for hundreds of movements. When an organism wants to move, signals travel from the brain to the skeletal muscle cells. The muscle cells then contract, or get shorter.

Strands of tough **connective tissue** connect the skeletal muscles to bones. These strands of tissue are called **tendons**. When a muscle that connects two bones gets shorter, the bones are pulled closer to each other. For example, tendons attach the biceps muscle to a bone in your shoulder and to a bone in your forearm. When the biceps muscle shortens, your forearm bends toward your shoulder.

The skeletal muscles often **work in pairs** to produce smooth, controlled motions by pulling, or contracting. When one muscle in the pair bends part of the body, the other muscle **extends** or straightens part of the body.

Bones of the Chicken

The **upper wing** consists of a **humerus**, which is at one end, and the **ulna** and the **radius** at the **lower wing**. These bones connect at the **elbow joint**. The rest of the wing is composed of modified hand bones.

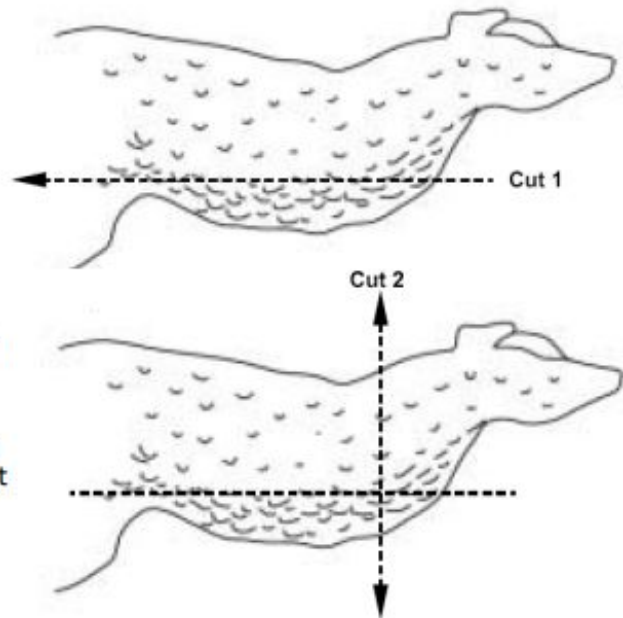
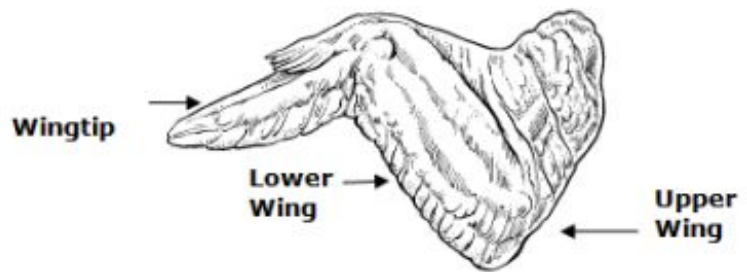


Materials

- dissection tray & instruments
- fresh chicken wing
- gloves
- goggles

Getting Under the Skin

- Examine the chicken wing, and compare it with the Figure to the right.
- Identify the upper wing, the lower wing, and the wingtip.
- Examine the wing at the point where it was removed from the body. Depending on the way the wing is cut, you might see cartilage and bone marrow.
- Using the scissors, cut down the middle of the skin, starting at the top end of the upper wing. Try not to cut through the muscles below the skin. Do this by piercing the skin and then slipping the scissors between the skin layer and the muscle. Cut until you reach the shoulder joint. (See cut 1.)
- Cut down the sides of the skin to make a T-shaped cut. Start at the first cut and cut away from it in both directions. Peel the skin and cut to loosen it. (Note: the chicken skin can be very difficult to remove. Take your time peeling it back so as not to damage the tissues underlying it. (See cut 2.)



Observations

Complete **Table 1, Observation Table**, as you complete your dissection and **Analysis Questions** as you complete the dissection.

Fat Look for yellowish tissue clumped together beneath the skin. This is fat tissue, made of fat cells.

Muscles

- Observe the muscles in the wing. They look like bundles of pale pink tissue.
- Find two muscles in the wing that bend and straighten the elbow joint. Each muscle pulls on the lower wing bones in one direction (the flexor bends the joint). Since the flexor cannot lengthen by itself to push the bone back to straighten the joint, another muscle pulls the bone in the opposite direction (extensor).
- Hold the wing down at the shoulder and alternately pull on each muscle. Observe what happens.

Tendons

- Tendons are shiny white tissues at the ends of the muscles that attach muscles to bones. Find as many tendons as you can on the chicken wing.
- Pull on a tendon to see how it helps the chicken move its wing.

Joints and Ligaments

- Two bones come together at a joint. Bend and straighten the elbow joint and observe how the bones fit together.
- Ligaments connect bones to other bones at joints. They look like a shiny white covering of the joint surfaces.
- Closely examine the elbow joint between the upper wing and the lower wing and identify the ligaments.

Chicken Wing Dissection Page 2

Cartilage

Between the bones is another shiny white material that is slippery. This is cartilage, which helps the bones move without grinding against one another, or without causing trauma.

Wing

- Move the wing again. Explore how the muscles, tendons, ligaments, and cartilage play roles in the wing's movement.
- Complete the Observation Table. When you have finished observing the wing and writing your notes, throw the chicken remains away. Wash all equipment in hot, soapy water.

Observations

Table 1 Observation Table

Tissue	Description (color, texture, etc.)	Tissue it attaches to
Skin	1.	2.
Fat	3.	4.
Muscle	5.	6.
Tendon	7.	8.
Ligament	9.	10.
Cartilage	11.	12.

Analysis (You do NOT need to write in complete sentences.)

13. What purpose does the connective tissue serve?

14. What type of tissue actually moves the chicken wing? _____

15. Why are tendons important to a muscle's ability to make the body move?

16. What tissue of the chicken wing is commonly referred to as the "meat"? _____

Making the Human Connection

- With your **left hand** grasp something with weight such as a heavy textbook or pencil pouch and hold it at your side. Place your **right hand** on your **upper left arm** so that you can feel your muscles move. Slowly bend your left arm to raise the weight. Then slowly straighten your left arm to lower it. Repeat this motion a few times until you can feel and see what is happening.

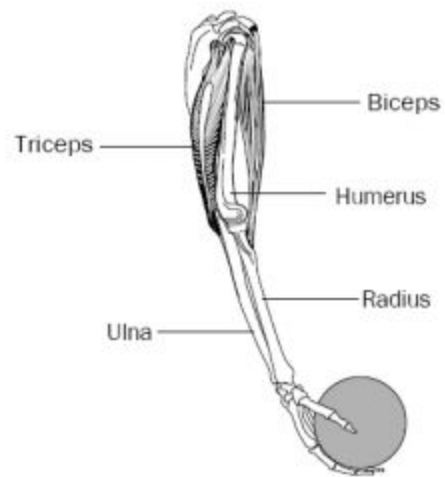
17. What joint did you use to lift the weight?

18. Explain which **muscle contracted** and which muscle **extended** as you raised the weight.

19. Then explain what happened to each muscle as you lowered the weight.

20. Which **bone(s)** in the arm moved?

21. Which bone(s) in the arm didn't move?



. Then, based upon your observations in this activity, explain either how the chicken wing or the human arm moves using all of the above terms in your answer. (2 points)

